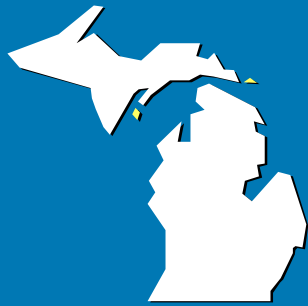



The Michigan MIKRO-GRAF

Volume XXXV, No. 4
February 2007

Inside this Issue

- Testicular Cancer
- Pneumocystis Myth-Nomer
- MSH Officers & Chairpersons
- Educational Exhibit
- Pfizer Employees
- NSH Awards
- 2006 Annual Reports
- NSH & ASCP Teleconferences
- 2007 Annual Meeting Update
- MSH Website Update



Tech Points

TESTICULAR CANCER

Paula J. Bober, BS, HT(ASCP)
MSH Vice President

Testicular cancer usually occurs between the ages of 15 and 35 and is one of the most common cancers in this age group. This cancer is also more common in Caucasian men than in men of other ethnic groups. If the disease is found early enough, the possibility of an excellent cure rate exists.

Testicles are part of the male reproductive system, located within the scrotum. The testis produce sperm through delicate coiled tubes called seminiferous tubules. Testosterone, a hormone produced in the testis, controls the development of masculine features like facial hair, a low voice and a muscular body. At birth, the testes descend into the scrotum through the inguinal canal, a tunnel in the groin.

... continued page 3

PNEUMOCYSTIS MYTH-NOMER

Peggy A. Wenk, HTL(ASCP)SLS
William Beaumont Hospital, Royal Oak, MI
Adopted from 2007 MSH Winter Seminar presentation

You may be seeing a new name for a pneumonia – *Pneumocystis jirovecii* (pronounced yee-row-vet-zee). However, it is our old familiar *Pneumocystis carinii*, with a new name. So how did that happen?

... continued page 6





(Testicular Cancer, cont. from page 1)

Abnormal testicular development and failure of the testicle to descend are signs of possible testicular cancer. Males who have a failure of testicular descent are 10 to 40 times more likely to develop testicular cancer. The risk is greater if the testis remains in the abdomen rather than the inguinal canal. Surgery to place the testis in the scrotum is helpful, and reduces the cancer risk if done before the age of six. Twenty-five percent of testicular cancer is found in normally descended testes.

Later in age, this cancer is usually found by the male himself or by his partner, and appears usually as a small lump. This lump could also be an infection or a non-cancerous growth. Some patients' initial complaint involves infertility, and symptoms may include swelling, pain, hardening of the testis, or a combination of these. Other patients describe pain in the lumbar back region, pain of gastrointestinal origin, respiratory pain, or may come to the doctor with a neck mass. These are usually signs of a more aggressive cancer, with possible metastases.

Histology of Testis Development

- Birth to age 4 (static phase): seminiferous tubules filled with small cuboidal cells with no definite lumen present, Leydig cells are usually not visible
- Age 4-10 (growth phase): tubules, tubular lumina and cells enlarge, tubules become tortuous
- Age 10 to puberty (maturation phase): tubular cells have mitoses; Leydig cells are prominent; spermatocyte differentiation is visible
- Adult (post-puberty): each testis weighs 15-19 g, measures 5x3 cm; takes 70 days for cells to mature from spermatogonium to primary spermatocyte to secondary spermatocyte to spermatid to spermatozoa; maturing is orderly along the length of the tubule, but not often present in the cross section of a biopsy

TESTICULAR CANCER CLASSIFICATIONS AS DESCRIBED BY WHO (WORLD HEALTH ORGANIZATION)

Intratubular Germ Cell Neoplasia

Seminomas

- Classic Seminoma
- Spermatocytic seminoma

Nonseminomatous germ cell tumors

- Embryonal carcinoma

- Yolk sac tumor / endodermal sinus tumor
- Teratoma: mature, immature, with malignant transformation
- Choriocarcinoma

Mixed or Unclassified Sex Cord Stromas

- Sertoli-Cell Tumors
- Gonadoblastomas
- Granulosa-Cell Tumor
- Leydig (Interstitial)-Cell Tumors
- Lymphomas and Leukemias

Each classification will be described below.

INTRATUBULAR GERM CELL NEOPLASIA

In 75% to 99% of testicular cancers, intratubular germ cell neoplasia was cited adjacent to the tumor, which can not go unmentioned. The only way to detect this is by doing a biopsy. If detected, the likelihood of developing testicular cancer is high. Orchiectomy (removal of the testis) is the recommended treatment.

Many other cancers are associated with testicular cancer. The most common in the United States is Germ-Cell Tumors, which accounts for 93%, while testicular lymphoma is 4% to 5%, and sex cord stroma is 3%. Germ cell tumors contain cells known as germ cells (germ means seed, this refers to the role of the male germ cells in making sperm cells). The two main germ cell tumors are classified as seminoma and nonseminoma.

- **Positive stains:** PLAP (Placental Alkaline Phosphatase, membrane accentuated, in 97% of cases), PAS without diastase (contains glycogen)
- **Treatment:** Removal of the testis

SEMINOMA

Seminomas are divided into two types, classic, which represents about 90% of all seminomas, and spermatocytic. Classic seminoma is spread through the lymph system, starting at the para-aortic lymph nodes, going to the mediastinal and supraclavicular nodes, then to the lung, liver, bone and adrenals where it is usually found late in the disease.

- **Gross description:** bulky, homogenous gray-white with lobulated and bulging cut surface, usually well demarcated, 50% involve entire testis, invasion of tunica albuginea in <10%, usually no hemorrhage, no cystic change, no extensive necrosis
- **Positive stains:** PLAP (almost all); ferritin, PAS with and without diastase, vimentin, angiotensin-1-converting enzyme (ACE)

...continued page 4



(Testicular Cancer, cont. from page 3)

- **Treatment:** radiation of the retroperitoneum, and chemotherapy with advanced disease

Spermatocytic Seminoma

This occurs around age 55 in descended testes (not in the mediastinum) with 1% to 2% of germ cell tumors. These are mostly benign with rare documented cases of metastases. They are associated with sarcomas showing skeletal muscle differentiation.

- **Gross description:** pale gray, mucoid edematous, soft, friable cut surface
- **Positive stains:** CAM5.2 (40%)
- **Negative stains:** PLAP, hCG, AFP, CEA, EMA, HPL, NSE, angiotensin-1-converting enzyme (ACE), keratin (may have focal staining).
- **EM:** cytoplasmic bridges between tumor cells resembles those between spermatocytes; thickening of plasma membrane, microtubules between cells; minimal or no glycogen

NONSEMINOMATOUS GERM-CELL TUMORS

Nonseminomatous germ-cell tumors exist in many forms as shown below. Eighty to 85% have complete response to chemotherapy, and most are cured.

- **Gross description:** variegated appearance since usually is a mixture of different components
- **Treatment:** surgery plus chemotherapy

Embryonal Carcinoma

This type usually occurs from 10-20 years of age and is not usually seen after the age of 50. Placental alkaline phosphatase (PLAP) and cytokeratin are usually elevated.

Yolk-Sac Carcinoma

Yolk-sac carcinoma is mostly found in infants and children. This accounts for 75% of the testicular cancer in this age group and it has a good prognosis.

It is rarely found in adults, but when found, it is aggressive and spreads mainly to the liver via the lymphatic system. AFP levels are usually higher and beta-hCG is not.

- **Gross description:** non-encapsulated, homogenous, yellow-white, mucinous, soft, multicystic; adult cases often have hemorrhage and necrosis
- **Positive stains:** AFP (diffuse through cytoplasm and hyaline globules, although pediatric tumors are often AFP negative), cytokeratin, variable CD30

- **EM:** epithelial cells with tight junctional complexes, apical microvilli, extracellular deposits of basal lamina, glycogen

Teratoma

This is a mixed germ-cell tumor. This tumor by itself only represents 2% to 3% of all testicular cancers. This tumor is usually benign because no malignant tissue is seen. However, degeneration to a cancerous form is seen and individuals have died from associated metastases. Teratomas can secrete beta-hCG and AFP, but neither is usually increased.

Teratomas have been known to degenerate into malignancies of poor prognosis. These include sarcomas, adenocarcinomas, and neuroepitheliomas.

- **Gross description:** large (5-10 cm), multinodular, heterogenous (solid, cartilaginous, cystic)
- **Treatment:** in children is surgery.

Choriocarcinoma

This is very rare and accounts for less than 1%, but is found as a component with another testicular tumor. It has early hematogenous and lymphatic spread and is the most aggressive. High levels of beta-hCG but normal levels of AFP are present.

- **Gross description:** small, may be replaced by fibrous scar with hemosiderin because it outgrows blood supply; resembles disintegrating clot
- **Positive stains:** hCG, HPL and EMA (syncytiotrophoblast, not cytotrophoblast), cytokeratin, cytokeratin 7 (may not stain other germ cell tumors), PLAP (50%), CEA (25%)

MIXED OR UNCLASSIFIED SEX CORD STROMAS

Sertoli-Cell Tumors

A scrotal mass is usually noted in these types of tumors. Only 10% are malignant and the treatment is surgical removal. They are usually found in the first 10 years of age, but can occur at any age.

- **Gross description:** firm small nodules, well circumscribed, homogenous gray-white to yellow, focally cystic or hemorrhagic
- **Positive stains:** vimentin, cytokeratin AE1/AE3, alpha-1-antitrypsin, neuron specific enolase, inhibin (variable), EMA, S100 (weak if present)
- **Negative stains:** PLAP
- **EM:** cells interconnected by desmosomes, abundant smooth ER, lipid droplets, Charcot-Bottcher filaments

...continued page 5



(Testicular Cancer, cont. from page 4)

Gonadoblastomas

This is a mixed germ cell and sex cord tumor usually seen in teenagers. Usually benign, they have been known to be associated with foci of malignant germ cell tumors 10% to 50% of the time. If patients only have gonadoblastoma, the prognosis is excellent, but if accompanied with foci prognosis, could be fatal.

- **Treatment:** bilateral gonadectomy, curative if no invasive component
- **Gross description:** tan-yellow with diffuse gritty calcifications
- **Positive stains:** anti-mullerian hormone
- **EM:** some cells show Charcot-Bottcher filaments of Sertoli cells

Granulosa- Cell Tumor

This is a non-germ cell tumor seen in infants and is non-malignant. Adults rarely have this tumor.

- **Gross description:** cream-colored to yellow-tan, rubbery-to-firm testicular tumors with extensive paratesticular spread
- **Positive stains:** chloroacetate esterase, myeloperoxidase, lysozyme, CD45/LCA, CD43
- **Negative stains:** CD20, CD3

Leydig (Interstitial)-Cell Tumors

These tumors can occur at any age, but is most common in age 60 and above. They secrete androgens and estrogens. Swelling of the testicles, gynecomastia and a decrease in sexual desire is noted. This particular tumor accounts for 1% to 3% of all testicular cancers, and only 7% to 10% metastasize.

- **Gross description:** solid, well-circumscribed nodules 5cm or less, golden-brown homogenous cut surface, 10% have extratesticular extension
- **Positive stains:** steroid hormones, vimentin, inhibin, calretinin, MelanA, keratin (variable)
- **Negative stains:** anti-mullerian hormone, S100 (usually)
- **EM:** abundant smooth endoplasmic reticulum, mitochondria with tubulovesicular cristae, Reinke's crystals (long tapered crystals)

Lymphomas and Leukemias

If lymphoma of the testis is found, it is usually not the initial site of the disease. If it is found to be the primary site, it is usually later in age (60 years and older).

- **Gross description:** white-tan-pink, fleshy, resembles seminoma, often extratesticular involvement
- **Positive stains:** CD20, LCA/CD45
- **Negative stains:** PLAP

Leukemia is usually found involving the testis if found in young patients who have had relapses after therapy or detected in autopsy of patients with acute leukemia (5%) and 30% with chronic leukemia.

- **Treatment:** radiation therapy, although bone marrow relapse is common

DIAGNOSIS

There are no early symptoms for this disease. The physical exam should be performed regularly, and testis should be able to move freely and have an even consistency. Any nodule present should be examined. When a tumor is suspected, ultrasonography should be done, which will exclude the likelihood of a hydrocele or epididymitis. It will also show whether a mass is present or not, and if it involves the tunica albuginea.

If a tumor is suspected, a biopsy should be done. After the diagnosis is made, clinical tests will be done to stage the patient. The tests done will be CT scan of the abdomen and pelvis, chest x-ray and beta-hCG, AFP, LDH and placental alkaline phosphatase. Sometimes a MRI or CT scan of the brain and a bone scan will be done if clinically indicated.

Stage I: The cancer has not spread to the lymph nodes and is limited to the testis

Stage II: The cancer has spread to the abdomen but not any distant organs via the lymph nodes

Stage III: The cancer has spread to one or more distant organs above the diaphragm (liver, lungs and or brain) via the lymph nodes.

TREATMENT

The treatment of testicular carcinoma is challenging in knowing which treatment to choose. The distinction between seminoma and nonseminoma is the main factor in deciding treatment. Pure seminomas, which account for approximately 40% of germ cell tumors, are extremely radiosensitive, while nonseminomas have to be treated with platinum-based chemotherapy or surgery. Seminomas that have any other cell types or that secrete alpha-fetoprotein require the more aggressive treatment prescribed for nonseminomatous tumors. Knowing which route to take is important to ensure the best patient care.

...continued page 6




(Testicular Cancer, cont. from page 5)

Lance Armstrong is a well-known cyclist who has won:

- The Tour de France 7 times
- The Clasica de San Sebastian 1 time
- The La Fleche Wallonne 1 time
- The World Cycling Champion 1 time

He was diagnosed on October 2, 1996 with nonseminomatous testicular cancer that had metastasized to his lungs, abdomen, and brain. After his surgery, he returned to cycling in 1999 and won many of the events mentioned above. He still is cycling, an indication that a good prognosis can exist after being diagnosed with testicular cancer.

REFERENCES

- <http://www.pathologyoutlines.com/testispf.html>
<http://www.cancernetwork.com/textbook/morev27.htm>
<http://health.yahoo.com/topic/testicularcancer>
<http://www.kantrowitz.com/cancer/causes.html>
http://en.wikipedia.org/wiki/Lance_Armstrong 



MSH member and Capital Area Career Center Instructor, Betsy Krummery was featured in Advance Newsmagazine!

Her article entitled *What's in a School? Innovative histotechnology program produces 'best and brightest' in the field*, was published in Vol. 19 • Issue 4 of Advance and can be accessed online at <http://laboratorian.advanceweb.com>.

Good Work Betsy!



(...cont. from page 1)

PNEUMOCYSTIS MYTH-NOMER

Peggy A. Wenk

It is an interstitial pneumonia that causes the alveolar septum to thicken, the lungs to become infiltrated with lymphocytes and plasma cells, and the alveolar spaces to be filled with flocculate material made up of protein and cell debris. The disease is spread from person to person in cough droplets. A person with *Pneumocystis pneumonia* (PCP) has the following symptoms:

- Febrile = runs a fever
- Tachypnea = rapid breathing
- Asphyxia = impaired oxygen and carbon dioxide exchange
- Hypoxia = decreased oxygen in the body
- Cyanosis = turning blue

PNEUMOCYSTIS CARINII

Before we can talk about why the new name, we need to consider how this microorganism got its original name. The *Pneumo* part is straight forward. It means air or gas, and is often used to designate the lungs. *Cystis* means bag-like or bladder-like, which, when looking at a GMS of the pneumocystis organism, is readily evident. But what does *carinii* mean?

In 1909, Carlos Chagas found these then-new microorganisms in the lungs of guinea pigs and marmosets that were infected with the parasite *Trypanosoma cruzi*. He thought this new organism was actually just a different phase of a life cycle of the *Trypanosoma cruzi*. This is understandable, as we now know *Pneumocystis* actually has three different shapes, depending upon what stage of its life cycle it is in:

- 1-2 um sporozoites
- 4-5 um trophozoites
- 6-8 um cysts

In 1910, Dr. Carini found this new microorganism in a guinea pig, but suspected that it was not part of the life cycle of the Trypanosome and theorized that it was a new, different microorganism. He contacted two investigators, the Delanoes, at the Pasteur Institute in Paris about this. By 1912, they had also found this organism in sewer rats that did *not* have *Trypanosoma cruzi*. They proposed that this was a new protozoa (parasite), and named it after Dr. Carini, who first proposed that this was a new entity. That is how it became known as *Pneumocystis carinii* (notice, with 2 "i" at the end).

...continued page 7

Earn 0.5 contact hours of continuing education by reading articles in the Michigan Society of Histotechnologists newsletter MIKRO-GRAF. MSH contact hours can be used for CMP required by ASCP BOR to maintain certification.

It is the responsibility of the participant to retain their MSH CE certificates as proof of continuing education.

^ ^

DATE OF ARTICLE: February 2007
TITLE: Testicular Cancer
AUTHOR: Paula J. Bober

DIRECTIONS:

1. Answer the following questions by circling the one (1) BEST answer for each question.
2. Complete the information required at the bottom of the page.
3. Submit questions & check (MSH) to: Peggy Wenk, HTL(ASCP)SLS, 3840 Elmhurst Rd., Waterford, MI 48328

To earn Continuing Education credit from MSH, completed form must be submitted within twelve (12) months of original date of the article.

1. PAS can be used to diagnose some testicular tumors because the cancer cells contain:
 - A. Fungus
 - B. Glycogen
 - C. Lipofucin
 - D. Mucin

2. Metastatic classic seminoma testicular cancer is most often found in all of the following organs **EXCEPT**:
 - A. Bone
 - B. Kidney
 - C. Liver
 - D. Lung

3. Which of the following testicular tumors is usually *negative* for PLAP staining?
 - A. Choriocarcinoma
 - B. Classic seminoma
 - C. Sertoli-Cell Tumor
 - D. Spermatocytic seminoma

4. TRUE or FALSE (circle one): Testicular cancer is more likely to occur if the testicle fails to descend.

PLEASE PRINT NEATLY DATE and YEAR *Completed/Submitted* Test: _____

NAME: _____

STREET: _____ APT. _____

CITY: _____ STATE: _____ ZIP: _____

PHONE: _____ Email: _____

_____ Yes	_____ No	I am a Michigan Society of Histotechnologists (MSH) member
_____ Yes	_____ No	I have included a check made out to "MSH" on US funds
		**FEE: \$5.00 for MSH members, \$10.00 for non-MSH members
_____ Yes	_____ No	I require a fee receipt for reimbursement from my employer

Certificate documenting 0.5 hours MSH continuing education (CE) will be mailed to the participant within 4 weeks.